



The expression of transforming growth factor- β 1 and type I collagen on the right ventricle of rat models with pulmonary arterial hypertension administered with pomegranate extract

Mahrus A. Rahman ^{1*}, Ilham Bondan Pramudiawan ¹, I Ketut Alit Utamayasa ¹

¹ Department Child Health Sciences, Faculty of Medicine, Universitas Airlangga, Surabaya 60131, INDONESIA

*Corresponding author: mahrus_rahman@yahoo.com

Abstract

Background: The level evaluation of transforming growth factor- β 1 (TGF- β 1) and type I collagen are the basic instructions for the occurrence of myocardial fibrosis process, especially in the right ventricle. Pomegranate extract is an alternative therapy for pulmonary arterial hypertension (PAH) by reducing systolic blood pressure and by inhibiting angiotensin-converting enzyme (ACE) serum.

Purpose: This study aims to determine the effectiveness of pomegranate extract on the fibrosis process due to PAH, particularly in the RV myocardium.

Method: This study used an experimental laboratory design with a randomized post-test only control group design. The samples were divided into four groups, i.e., K1 and K2, as control groups and E1 with E2 as treatment groups. The data analysis used the ANOVA test and multiple comparisons or Least Significance Difference (LSD). The Kruskal Wallis test was used if the distributed data was not normal.

Results: There were no significant differences in body weight between the groups in K1, E1, K2, and E2. The average systolic and diastolic pressure and pulmonary artery between the E1 and E2 groups were lower than those in the K1 and K2 control groups. The average amount of cells and the immunohistochemical results expressing TGF- β 1 and type I collagen in the E1 and E2 groups were less than those in the K1 and K2 groups.

Conclusion: Pomegranate extract effectively decreases the number of cells expressing TGF- β 1 and type I collagen in the right ventricle of the rat models of pulmonary arterial hypertension.

Keywords: pulmonary artery, pomegranate, fibrosis, right ventricle

Rahman MA, Pramudiawan IB, Utamayasa IKA (2020) The expression of transforming growth factor- β 1 and type I collagen on the right ventricle of rat models with pulmonary arterial hypertension administered with pomegranate extract. *Eurasia J Biosci* 14: 3719-3723.

© 2020 Rahman et al.

This is an open-access article distributed under the terms of the Creative Commons Attribution License.

INTRODUCTION

Pulmonary arterial hypertension (PAH) is a condition in which an increase in the average pulmonary artery pressure exceeds 25 mmHg at rest (Wardle & Tulloh, 2012). This condition occurs due to pulmonary arterial remodeling and changes in homeostasis of vasoactive substances in endothelium resulting in vasoconstriction of the pulmonary arteries (Humbert, Sitbon, and Simonneau, 2004; Setianingsih *et al.*, 2019). Pulmonary arterial hypertension also causes remodeling of the cardiac muscle, especially the right ventricle (RV) in the form of myocyte hypertrophy, activation and fibroblast hyperplasia, and extracellular collagen deposition known as fibrosis. Myocardial fibrosis causes myocardial stiffness to interfere with the diastolic and systolic function that can lead to heart failure and death (Fan *et al.*, 2012).

Transforming growth factor- β 1 (TGF- β 1) and type I collagen are important markers in the remodeling process of myocardial fibrosis so that the evaluation of TGF- β 1 levels and type I collagen can be used as the basic instructions of myocardial fibrosis process (Lez, Pez, and Di'Ez, 2004; Fan *et al.*, 2012). PAH therapy focuses on pulmonary arterial vasodilation. These therapies include calcium channel blockers, prostanoids, endothelin antagonists, and phosphodiesterase five inhibitors (Raja and Raja, 2011). None of these therapies are curative and have sufficient side effects, so the search for new therapeutic strategies continues (Duarte, Hanson, and Machado, 2013).

One of the alternative therapies is to use natural substances, such as pomegranate extract (PE), which

Received: November 2019

Accepted: April 2020

Printed: September 2020

has the potential to inhibit cancer cells by inducing apoptosis. Pomegranate extract also has anti-bacterial, anti-viral, antioxidant, anti-tumor, estrogenic effects which is effective in reducing the risk of cardiovascular disease, including oxidation of low-density lipoprotein (LDL), restoring hardening of the artery walls, reducing systolic blood pressure by inhibiting serum angiotensin-converting enzyme (ACE) (Ignarro, Balestrieri, and Napoli, 2007; Jurenka, 2008; Kholifah, 2010; Haber, Joy and Largent, 2011). The content in PE may also function as an anti-proliferative and anti-inflammatory in cardiovascular disease, as well as anti-fibrotic liver in rat models (Seeram *et al.*, 2005; Haber, Joy and Largent, 2011; Yuniarti *et al.*, 2013; Javanmard and Rafiee, 2015). In addition to the studies that have been carried out, the pomegranates are claimed to have no side effects, making it safe to use as an alternative therapy (Vidal *et al.*, 2003; Jurenka, 2008; Dadvar-Khan, & Ghanian, 2016).

This study was conducted to determine the effectiveness of pomegranate extract on the fibrosis process due to PAH, particularly in the RV myocardium. The study uses monocrotaline-induced pulmonary arterial hypertension in rats as a model. This method is considered easier than making hypoxia using hypobaric chambers (Voelkel and Tuder, 2000).

METHOD

This study used an experimental laboratory design with a randomized post-test only control group design. The research group was derived from one population which had the same age, gender, and variant. The population in this study were 24 male white rats (*Rattus norvegicus*) Sprague Dawley strain, three months old with a bodyweight of 300-500 grams. Three months old rats were equivalent to 7.5 years old human (Andreollo *et al.*, 2012). There were four groups in this study, (K1) was a control group of rat models that only received CMC for two weeks, (K2) was a control group of rat models that only received CMC for four weeks, (E1) was an experimental/treatment group of PAH rat models that received CMC and pomegranate extract for two weeks, and (E2) was an experimental/treatment group of PAH rat models that received CMC and pomegranate extract for four weeks.

The substances for making preparations in this study which would later be examined using immunohistochemical techniques included the cardiac muscle tissue of the right ventricle, the monoclonal antibody against TGF- β 1 and specific antibodies against type I collagen, hematoxylin-eosin, acetone, xylol, 100% alcohol, 90% alcohol, 90% alcohol, 80% alcohol, 70% alcohol, aquadestilata, phosphate-buffered saline (PBS), streptavidin-biotin peroxidase, 0.5% H₂O₂, 3% trypsin, and substrate. New preparations were made every day for 12 rats that received pomegranate extract

treatment. Rats with a bodyweight of 300 grams, with an extract dose of 150 mg/kg body weight, required 45 mg of extract or 3 ml of standardized pomegranate extract suspension. The measurements of pulmonary artery pressure were performed after 14 days and 28 days of subcutaneous monocrotaline injection in each group. Cardiac tissue was prepared as an examination substance of TGF- β 1 expression and type I collagen by immunohistochemical techniques. This study had received ethical approval from the Department/SMF Child Health Sciences, Medical Faculty, Universitas Airlangga No. 400-KE of 2015 and animal care and use committee (ACUC) Faculty of Veterinary Medicine, Universitas Airlangga No. 603-KE of 2018.

The data collection was carried out in a controlled and monitored environment with the consideration that all conditions were attempted to be the same and controllable. For data processing and analysis with a statistical computer program, ANOVA test, and Multiple Comparison or Least Significance Difference (LSD) were used. If the normality test of distributed data was not normal, the test was proceeded with the Kruskal Wallis test to monitor whether there were any differences in the average of TGF- β 1 expression and type I collagen in the whole group. The significance level in the statistical tests used in this study was 0.05.

RESULTS

Two rats were found dead on the 7th and 11th day of observation, and both were in the control groups of two-week treatment and four-week treatment, respectively. The cardiac organs of both rats were taken and observed. The rats' body weights were weighed at the beginning before treatment, and the final weights were weighed at the end of 2- and 4-weeks observations. The weight loss was found in the groups terminated in the 4th week, although the difference was not statistically significant. There were no significant differences in body weight between the groups in K1, E1, K2, or E2 at the beginning and the end of the study. In addition, there were no significant differences between the initial and final body weights in each group.

The average systolic and diastolic pressures of the pulmonary artery in the groups of rats receiving PE therapy were lower than those in the control groups with a significant difference ($p = 0.002$), both at 2nd and 4th week of observations. The same phenomenon happened in the average pulmonary artery pressures (MAP = Mean Arterial Pressure), as shown in **Table 2**. The average systolic and diastolic pressure between the E1 and E2 groups were lower than those in K1 and K2 control groups. There were no significant differences in the average systolic and diastolic pressures between the K1 and K2 control groups and the E1 and E2 treatment groups. The average pulmonary artery pressures between the E1 and E2 groups were lower than in those

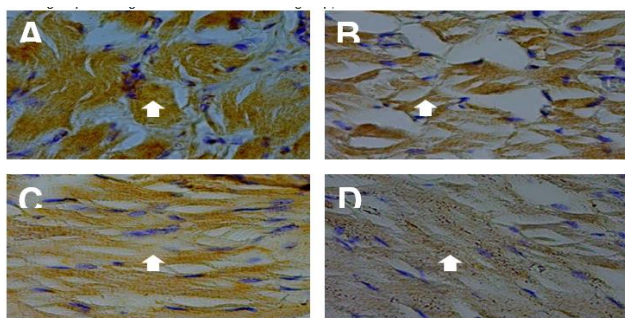


Fig. 1. TGF-β1 expression in the heart muscle of rat models. Figure A for K1 group, B for E1 group, C for K2 group, and D for E2 group at 400x enlargement. The arrows indicate the cells that express TGF-β1 in the right ventricular heart muscle. The strong expression occurs in the K1 and K2 groups and the number of expressions is lower than E1 and E2, which received pomegranate extracts.

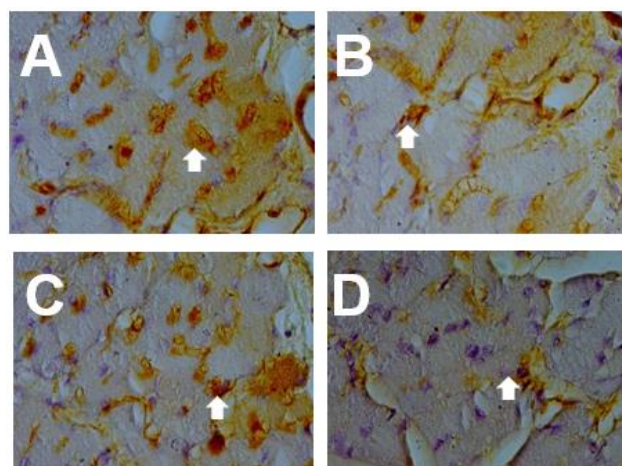


Fig. 2. Collagen expression in rat models hearts muscle. Figure A for K1 group, B for E1 group, C for K2 group, and D for E2 group at 400x enlargement. The arrows indicate the cells that express Collagen in the right ventricular heart muscle. The strong expression occurs in the K1 and K2 groups, and the number of expressions is lower than E1 and E2 which received pomegranate extracts.

K1 and K2 control groups. There were no significant differences in the average systolic and diastolic pressures between the K1 and K2 control groups and the E1 and E2 treatment groups.

Immunohistochemical techniques were used to examine the TGF-β1 expression and type I collagen in the cardiac muscle of the right ventricle. The identification of TGF-β1 expression and type I collagen aimed to observe the inflammatory process that was accompanied by fibrogenesis in the cardiac muscle tissue of the right ventricle in the control and treatment groups. The immunohistochemistry description indicated that the cells expressed the examined protein was brown, whereas the cells that did not express the examined protein was not (transparent). The brown color resulted from the protein reactions that were checked by their specific antibodies. Cell counts were carried out in 10 high power field preparations using 400x magnification and presented as the average. The examination results of preparations with immunohistochemical techniques indicated that the PAH model animals that received pomegranate extract had lower expression of TGF-β1 and typed I collagen compared to the control groups.

In terms of the number of cells that expressed TGF-β1, the average amount of cells that expressed TGF-β1 in the K2 group was higher than those in the K1 group, which was statistically significant. The average amount of cells that expressed TGF-β1 in the E1 group was less than those in K1 and K2 groups, which was statistically significant. The average amount of cells that expressed TGF-β1 in the E2 groups was less than those in the K1 and K2 groups, which was statistically significant. The average amount of cells that expressed TGF-β1 in the E1 group was not significantly different from those in the E2 group. The average amount of cells that expressed TGF-β1 in K1, E1, K2, and E2 groups is shown in Table 4.

Table 1. The Rat Models' Weight

Group	Initial Weight	Final Weight	P
	Mean ± SD (Min-Max)	Mean ± SD (Min-Max)	
K 1	303.83 ± 37.46 (265-355)	294.00 ± 39.81 (236-351)	0.457
E 1	312.50 ± 62.40 (262-433)	318.50 ± 66.46 (254-311)	0.172
K 2	319.00 ± 26.57 (285-351)	294.40 ± 53.23 (220-357)	0.453
E 2	300.33 ± 18.55 (280-327)	275.33 ± 33.57 (220-311)	0.064
P	0.663	0.531	

Table 2. The Average Systolic and Diastolic Pulmonary Artery Pressures

Group	Systolic SD	Diastolic SD
	Mean ± SD (Min-Max)	Mean ± SD (Min-Max)
K 1	66.64 ± 11.07 ^a (45.9-79.1)	37.90 ± 4.26 ^a (30.9-42.8)
E 1	41.47 ± 13.47 ^b (20.5-57.4)	20.62 ± 7.25 ^b (10.7-32.6)
K 2	65.03 ± 5.50 ^a (59.5-71.4)	37.28 ± 7.99 ^a (26.9-44.1)
E 2	44.73 ± 12.66 ^b (26.0-60.6)	26.28 ± 9.15 ^b (13.7-38.2)
p	0.002	0.002

The average amount of cells that expressed type I collagen in the E1 group was less than those in K1 and K2 groups, which was a statistically significant difference. The average amount of cells that expressed type I collagen in the E2 group was less than those in K1 and K2 groups, which was statistically significant. The average amount of cells that expressed type I collagen in the E1 group was not significantly different from the E2 group.

Table 3. The Average Pulmonary Arterial Pressure (mPAP=Mean Artery Pressure)

Group	mPAP
	Mean \pm SD (Min-Max)
K 1	47.8 \pm 5.58 ^a (39.03-53.63)
E 1	27.57 \pm 9.17 ^b (13.97-40.87)
K 2	46.53 \pm 5.53 ^a (40.50-53.20)
E 2	32.43 \pm 9.64 ^b (20.47-41.67)
p	0.0001

* Significant at $\alpha = 0.05$ ^{ab} superscript indicates no significant differences between groups based on the LSD double comparison test ($p < 0.05$).

Table 4. The Average Cell Numbers representing TGF- β 1 and Type I Collagen in PAH Rat models

Group	TGF- β 1	Type I Collagen
	Mean \pm SD (Min-Max)	Mean \pm SD (Min-Max)
K 1	9.17 \pm 0.53 ^a (8.64-9.7)	10.83 \pm 0.477 ^a (10.353-11.307)
E 1	6.33 \pm 0.422 ^b (5.908-6.752)	8.00 \pm 0.447 ^b (7.553-8.447)
K 2	12.83 \pm 1.302 (11.528-14.132)	14.17 \pm 0.910 ^c (13.26-15.08)
E 2	6.33 \pm 1.085 ^b (5.245-7.415)	6.67 \pm 0.615 ^b (6.055-7.285)
p	<0.0001	<0.0001

Note: Different ^{abc} superscripts indicate significant differences between groups based on the LSD double comparison test ($p < 0.05$).

DISCUSSION

Transforming Growth Factor- β 1 is the main profibrogenic cytokine and the excessive TGF- β 1 expression, which is associated with fibrosis progression (Wei *et al.*, 2015). Pomegranate extract inhibits fibrosis through cytokine regulatory pathways with antioxidant activity, decreases TGF- β 1 levels, and inhibits collagen synthesis (Wei *et al.*, 2015). TGF- β 1 signal inhibition by PE could be utilized as an inhibition marker of right ventricular fibrosis due to PAH. In this study, the results indicated that the number of cells expressing TGF- β 1 in the right ventricle of PAH rat models that received PE was less than those in the control groups. Tissue injury

on PAH due to monocrotaline or shear stress would trigger inflammation through the arachidonic acid cascade breakdown from the phospholipid membrane by the phospholipase A2 enzyme. The ellagic acid content in pomegranate extract inhibited the TGF- β 1 signal through the inflammatory and angiotensin pathway (Corbett *et al.*, 2010).

The results of this study indicated that the number of cells expressing type I collagen in the 4-week control group (K2) was statistically greater than the 2-week control group (K1). The number of cells expressing type I collagen for the treatment groups was statistically lower, but the number of cells expressing type I collagen for 2-week (E1 group) and 4-week (E2 PE group) indicated no significant difference. Fibrosis was defined as an enhancement collagen concentration in organs and dominated by type I collagen (Lez, Pez and Di'Ez, 2004). Increased collagen synthesis and decreased collagen degradation enhanced the type I collagen concentration (Liu *et al.*, 2015). The result of this study also had similarities with the study conducted by Saputro (2013), who obtained the increasing concentration of type I collagen in rat models with burn trauma that received PE therapy.

The PE effectiveness in reducing TGF- β 1 and type I collagen concentrations at 2-week and 4-week indicated that PE could inhibit the initial process of fibrogenesis while increasing the fibrosis resolution. In clinical practices, PE is expected to prevent fibrosis and reduce the fibrosis degree that has already occurred. The use of PE is expected to be a consideration as subsidiary therapy, following the existence of the standard therapies to reduce morbidity and mortality related to PAH.

CONCLUSION

In this study, pomegranate extract (PE) has been verified to reduce the number of cells expressing TGF- β 1 and type I collagen concentration in the right ventricle of the rat models with pulmonary arterial hypertension.

REFERENCES

- Andreollo, N. A., Santos, E. F. D., Araújo, M. R., & Lopes, L. R. (2012). Rat's age versus human's age: what is the relationship?. *ABCD. Arquivos Brasileiros de Cirurgia Digestiva (São Paulo)*, 25(1), 49-51.
- Corbett, S., Daniel, J., Drayton, R., Field, M., Steinhardt, R., & Garrett, N. (2010). Evaluation of the anti-inflammatory effects of ellagic acid. *Journal of PeriAnesthesia Nursing*, 25(4), 214-220.
- Dadvar-Khan, F., & Ghanian, M. (2016). Strategic Management of Rural Tourism Towards Gender-Sensitive Planning. *International Journal of Geography and Geology*, 5(11), 236-248.
- Duarte, J., Hanson, R., & Machado, R. (2013) 'Pharmacologic Treatments for Pulmonary Hypertension', *Future Cardiol*, 9, pp. 335-49.
- Fan, D., Takawale, A., Lee, J., & Kassiri, Z. (2012). Cardiac fibroblasts, fibrosis and extracellular matrix remodeling in heart disease. *Fibrogenesis & tissue repair*, 5(1), 15.
- Haber, S., Joy, J. & Largent, R. (2011) 'Antioxidant and Antiatherogenic Effects of Pomegranate', *Am J Health Syst Pharm*, 68, pp. 1302-5.

- Humbert, M., Sitbon, O., & Simonneau, G. (2004). Treatment of pulmonary arterial hypertension. *New England Journal of Medicine*, 351(14), 1425-1436.
- Ignarro, L., Balestrieri, M. & Napoli, C. (2007) 'Nutrition, Physical Activity, and Cardiovascular Disease: An Update', *Cardiovasc Res*, 73, pp. 326–40.
- Javanmard, D. & Rafiee, L. (2015) 'Antiangiogenic and Antiproliferative Effects of Black Pomegranate Peel Extract on Melanoma Cell Line', *RPS*, 10, pp. 117–24.
- Jurenka, J. (2008) 'Therapeutic Applications of Pomegranate (Punica Granatum L): A Review', *Altern Med Rev*, 13, pp. 129–44.
- Kholifah, M. (2010) 'Pengaruh Konsentrasi Ekstrak Etanol Buah Delima (Punica Granatum Linn.) Terhadap Peningkatan Apoptosis Sel Kanker Lidah Manusia Sp- C1 in Vitro', *Biomed*, 2, pp. 72–80.
- Lez, A., Pez, B. & Di'Ez, J. (2004) 'Fibrosis in Hypertensive Heart Disease: Role of the Renin-Angiotensin-Aldosterone System', *Med Clin N Am*, 88, pp. 83–97.
- Liu, P. *et al.* (2015) 'Effects of baicalin on collagen I and collagen III expression in pulmonary arteries of rats with hypoxic pulmonary hypertension', *Int J Mol Med*, 35(4), pp. 901–8.
- Raja, S. & Raja, S. (2011) 'Treating Pulmonary Arterial Hypertension: Current Treatments and Future Prospects', *Ther Adv Chronic Dis*, 2(6), pp. 359–370.
- Saputro, I. (2013) *Regulasi Fibrosis Pada Kulit Tikus Putih (Rattus Norvegicus) Dengan Luka Bakar Derajat 2 Yang Mendapat Terapi Ekstrak Buah Delima Terstandard Elagic Acid 40% (Studi Eksperimental Laboratorium)*. Universitas Airlangga.
- Seeram, N. P., Adams, L. S., Henning, S. M., Niu, Y., Zhang, Y., Nair, M. G., & Heber, D. (2005). In vitro antiproliferative, apoptotic and antioxidant activities of punicalagin, ellagic acid and a total pomegranate tannin extract are enhanced in combination with other polyphenols as found in pomegranate juice. *The Journal of nutritional biochemistry*, 16(6), 360-367.
- Setianingsih, H., Sudiana, I. K., & Suryokusumo, G. (2019). Endothelial Dysfunction Improvement Mechanism By Hyperbaric Oxygen In Sprague Dawley By High-Cholesterol Diet. In *IOP Conference Series: Earth and Environmental Science* (Vol. 217, No. 1, p. 012052). IOP Publishing.
- Vidal, A., Fallarero, A., Peña, B. R., Medina, M. E., Gra, B., Rivera, F., ... & Vuorela, P. M. (2003). Studies on the toxicity of Punica granatum L. (Punicaceae) whole fruit extracts. *Journal of ethnopharmacology*, 89(2-3), 295-300.
- Voelkel, N. & Tuder, R. (2000) 'Hypoxia-Induced Pulmonary Vascular Remodeling: A Model for What Human Disease?', *J Clin Invest*, 106, pp. 733–8.
- Wardle, A. & Tulloh, R. (2012) 'Update on Pulmonary Arterial Hypertension in Children: Management Strategies and Clinical Utility of Sildenafil', *Pediatric Health Med Ther*, 3, pp. 59–67.
- Wei, X. L., Fang, R. T., Yang, Y. H., Bi, X. Y., Ren, G. X., Luo, A. L., ... & Zang, W. J. (2015). Protective effects of extracts from Pomegranate peels and seeds on liver fibrosis induced by carbon tetrachloride in rats. *BMC complementary and alternative medicine*, 15(1), 389.
- Yuniarti, W. M., Handajani, R., Kusumobroto, H. O., & Sudiana, K. (2013). Ekstrak Buah Delima Terstandar Menurunkan Derajat Fibrosis Hati pada Hewan Model Tikus Putih. *Jurnal Veteriner*, 14(4), 511-518.