



## Hydrometrocolpos in neonate with imperforate hymen: Diagnosis and treatment

Eighty Mardiyani Kurniawati <sup>1\*</sup>, Achmad Zaki <sup>1</sup>, Jimmy Yanuar <sup>1</sup>, Sri Andreani Utomo <sup>2</sup>

<sup>1</sup> Department of Obstetrics and Gynaecology, Faculty of Medicine, Universitas Airlangga - Dr. Soetomo Teaching Hospital, Surabaya Surabaya 60131, INDONESIA

<sup>2</sup> Department of Radiology, Faculty of Medicine, Universitas Airlangga - Dr. Soetomo Teaching Hospital, Surabaya Surabaya 60131, INDONESIA

\*Corresponding author: [ety\\_emka@yahoo.com](mailto:ety_emka@yahoo.com)

### Abstract

**Background:** Hydrometrocolpos is a rare condition. Hydrometrocolpos is a cystic dilatation of the uterovaginal with fluid accumulation due to a combination of stimulation of secretory glands of the reproductive tract and vaginal obstruction such as imperforate hymen, transverse vaginal septum or vaginal atresia. **Purpose:** In this paper, the researchers would report the rare case of hydrometrocolpos in the newborns with the imperforate hymen. **Method:** The researchers report a case a 24-year-old primigravida at term was referred to the hospital with the suspected fetal congenital anomalies. It shows prenatal fetal ultrasonography with intra-abdominal cystic mass. Then, a female neonate was delivered vaginally with a good Apgar score. **Result:** Physical examination of the neonate revealed a cystic mass intralabial caused by the bulging membrane in the vaginal introitus. Ultrasonography and magnetic resonance imaging postnatal further defined a cystic mass in the pelvic extending caudally into the vagina and mild left hydronephrosis which is the result of mass compression. Therefore, the diagnosis of hydrometrocolpos with the imperforate hymen was established. **Conclusion:** The treatment by hymenotomy and marsupialization to the evacuated hydrometrocolpos was performed. The infants are recovered fully after the treatment and show postoperative ultrasonography resolution of hydrometrocolpos and hydronephrosis.

**Keywords:** diagnosis, Hydrometrocolpos, imperforate hymen, treatment

Kurniawati EM, Zaki A, Yanuar J, Utomo SA (2020) Hydrometrocolpos in neonate with imperforate hymen: Diagnosis and treatment. *Eurasia J Biosci* 14: 3273-3277.

© 2020 Kurniawati et al.

This is an open-access article distributed under the terms of the Creative Commons Attribution License.

### INTRODUCTION

A congenital disorder is a common and major case which were experienced by many babies all over the world. Congenital heart disease becomes a common problem and may lead to heart failure in the future (Bableswhar, Al Amer, & Kalis, 2018. Smit-Fun, & Buhre, 2019). There are some other congenital disorder which rarely happened and commonly classified to the genital cases (Karteris, et al. 2010 Azinar, et al. 2017).

The imperforate hymen is a congenital abnormality in the female genital tract which also classified as a case. The study reported the incidence of the imperforate hymen in the infants about 0.014 to 0.1% and accompanied by the hydrometrocolpos which is less than 1/16,000 of the female births (Karteris, et al. 2010).

The imperforate hymen usually occurs without symptoms until the occurrence of menstruation in a woman. However, due to the influence of estrogen from the uterovaginal mucosa, the fetus produces mucus fluid that can accumulate in the vagina and uterus causing hydrometrocolpos. This disorder can cause a mechanical suppressive effect against the urethra and

bladder, causing the symptoms of obstruction of the urinary tract that can cause hydroureteronephrosis (Eksioglu, et al. 2012).). In this paper, the researchers would report the rare case of hydrometrocolpos in the newborns with the imperforate hymen.

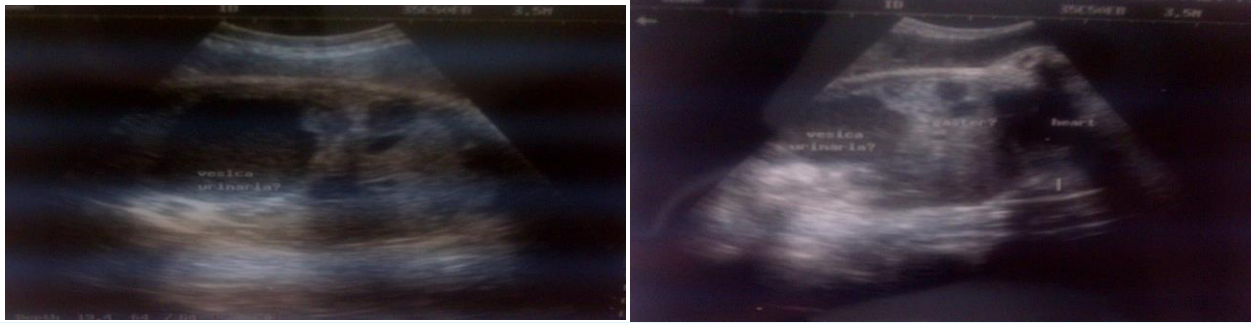### THE CASE PRESENTATION

This patient is a newborn baby from a pregnant woman at term who were referred to Dr. Soetomo Regional Public Hospital with a diagnosis of primigravida 40/41 weeks of the gestation+ in the labor of the first stage in latent phase+ with the suspected congenital fetal anomalies. In the prenatal ultrasound examination at the emergency room, Dr. Soetomo Regional Public ospital reveals fetuses with abdominal cystic mass as seen in **Fig. 1**. The patients are scheduled for the repeated prenatal ultrasound examination at the Fetomaternal for the diagnosis of congenital anomalies.

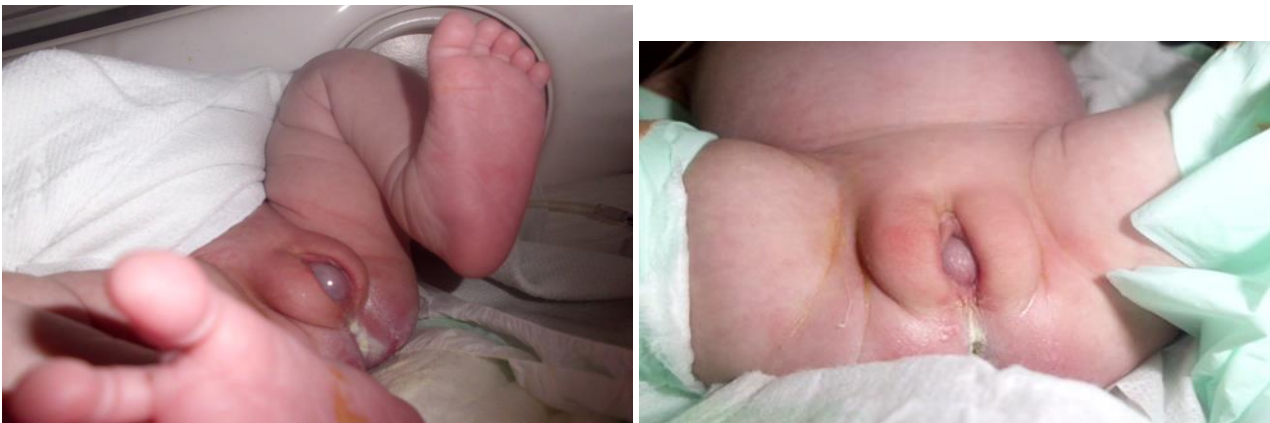Received: November 2019

Accepted: March 2020

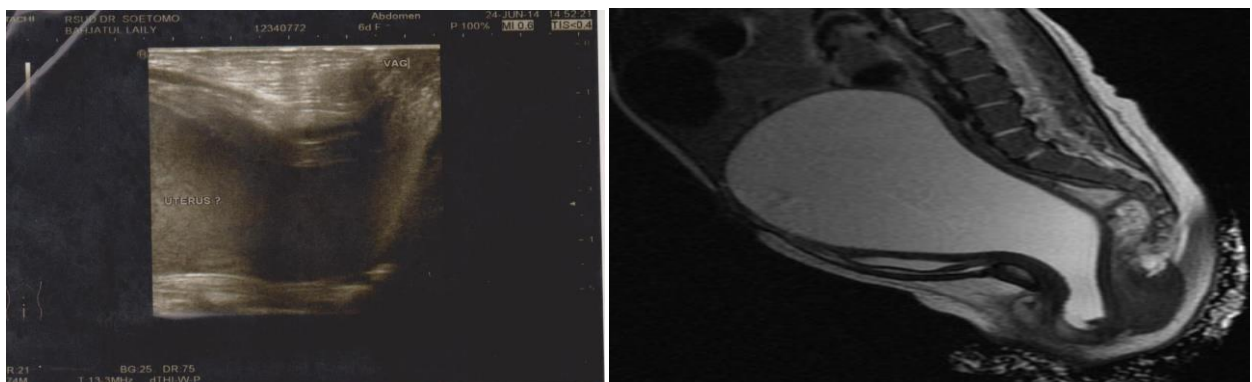
Printed: September 2020



**Fig. 1.** Prenatal ultrasound: abdominl cystic mass



**Fig. 2.** Intralabial cystic mass



**Fig. 3.** Postnatal ultrasound and MRI Results

In a way, the baby's mother gave birth spontaneously on June 19, 2014. A female baby was born with a weight of 3800 grams, a length of 49 cm with an Apgar score of 7-8. The examination reveals a female baby with the interlabial cystic mass as seen in **Fig. 2**.

At the postnatal ultrasound examination obtained the cystic lesion with the internal moving echo in it the size of 5 x 4.85 x 7 cm in the pockets between bladder and rectum, uterine cavity was not found and concluded as the imperforate hymen as seen in **Fig. 3**. On postnatal, MRI reveal lesions shaped like cavity of the thin uterus wall that is between bladder and rectum that continues into the vaginal area, lesions appeared pushed the bladder to the right, the border of the bladder, rectum and other structures still looked firm. There is a light

ectasis in the pelvicalyceal system of the left kidney that concluded hydronephrosis as seen in **Fig. 3**.

Hymenotomy and marsupialization was performed to evacuate the fluid in the hydrometrocolpos. On the 9th daycare after the surgery, the baby was discharged from the hospital in a good outcome. On the ultrasound evaluation of postoperative reveals that no longer liquid in the uterine cavity and no hydronephrosis was found. At 1-month follow-up, after surgery, no symptoms were reported.

## DISCUSSION

Hydrometrocolpos in the case of imperforate hymen is usually discovered during prenatal as a cystic mass in

the abdomen in the female fetus. The prenatal diagnosis of the imperforate hymen with the earliest hydrometrocolpos has been reported at 25 weeks of pregnancy, but most cases are diagnosed later in the pregnancy or after birth. The differential diagnosis of a cystic mass in the abdomen of the fetus during the prenatal i.e. mainly the ovarian cysts. Certain findings on the ultrasound examination revealed that the female sex of the fetus and vagina labium divided by the bulged hymen membrane (Vitale, Cigliano, & Vallone, 2013. GÜRATFi, et al. 2000. Tseng, et al. 2008). Imperforate hymen is a congenital anomaly that has existed since the fetus but the diagnosis during the prenatal period is still rare. This is because these disorders rarely found together with the hydrocolpos and the hydrometrocolpos during intrauterine are difficult to diagnose (Adaletli, et al. 2007; Toor, et al, 2016).

Other urogenital abnormalities can accompany abnormalities in the imperforate hymen. The ultrasound to evaluate the imperforate hymen should also be accompanied by an evaluation of other urogenital abnormalities although ultrasound is highly important for the evaluation of fetal anatomy and abnormality. The examination of magnetic resonance imaging (MRI) is an alternative modality for some cases of prenatal abnormalities. MRI can show the exact location and the extension of the cystic mass of the middle of the abdomen to the perineum. The bladder looks clear on MRI. The cystic mass could be diagnosed as hydrocolpos because it extends to the perineum and the bladder abnormalities could be excluded (Adaletli, et al. 2007).

In the case of this report, prenatal diagnosis with hydrometrocolpos imperforate hymen could not be diagnosed. This condition may occur because the ultrasound examination is done during early pregnancy so that the cystic mass has not been formed or are still small so it does not appear. An ultrasound examination during the pregnancy period appears the cystic mass in the abdomen. This is following the literature that most hydrometrocolpos cases were diagnosed in late pregnancy or after birth. This is because of the amount of fluid mucus that accumulates in uterovaginal so that intra-abdominal cystic mass display will be more obvious.

Imperforate hymen abnormalities with hydrometrocolpos are a very rare incidence. Approximately 1:16,000 of the female fetus is born with the imperforate hymen. So that the suspicion of this disorder is often not considered. The ultrasound examination did not mention the gender of the fetus. Whereas if an ultrasound examination obtained from the fetal gender and women's vagina labium that were separated by the bulging membrane of the imperforate hymen, the diagnosis with the hydrometrocolpos will be more-assertive.

### Postnatal diagnosis hydrometrocolpos

In this case, the diagnosis of hydrometrocolpos in the neonates with the postnatal clinical imperforate hymen can be found. The main complaint is an abdominal mass that can be accompanied by respiratory distress, vomiting, constipation, obstructive uropathy, and urogenital abnormalities. Sometimes ascites were found in the neonates. On the physical examination of the hymen, the membrane reveals the genital protruding at the introitus vagina. Furthermore, the diagnosis can be confirmed by ultrasound (Gupta, Bajwa, & Gupta, 2014).

The findings on the ultrasound examination are most often in the form of a cystic mass in the middle of the abdomen or pelvis. On the ultrasound examination could be found as a significant accumulation of echogenic fluid in the vagina. The ultrasound examination of the fetus aims to confirm the diagnosis of hydrometrocolpos and also aims to look for abnormalities as the cause of the obstruction. Other urogenital abnormalities can accompany the imperforate hymen because the ultrasound for the evaluation of the imperforate hymen should also be accompanied by an evaluation of other urogenital disorders (Rouma, 2011).

In some cases, the clinical examination and ultrasound are sometimes still difficult to determine the cause of hydrometrocolpos and other urogenital abnormalities. Postnatal MRI is highly useful in the cases with a diagnosis that remains unclear. MRI has the advantage of non-invasive and has no radiation exposure. More than that MRI can clearly distinguish the anatomy of the perineum, determining the septal abnormalities of the uterus, vaginal septum, cloacal and urogenital sinus. MRI may demonstrate the dilatation of the vagina and the protrusion of the membrane at the introitus of the vagina in the case of the imperforate hymen (Gupta, Bajwa, & Gupta, 2014).

In this case, after the baby was born, on the physical examination, they found out that the cystic mass between the labium minor because of the hymen membrane protrusion at the vaginal introitus and fast-growing mass while the baby was crying. At first, they were diagnosed as a cyst mass suspicion with the interlabial of Gartner cyst. An ultrasound was performed to confirm the diagnosis. There is an internal cystic lesion with a possibility of moving echo of uterine secretions that contain the appropriate picture of the imperforate hymen in the neonates (**Fig. 3**). The postnatal diagnosis of the imperforate hymen with the hydrometrocolpos, in this case, has been made clear due to the history of an abdominal cystic mass in the fetus during the prenatal. Then, a female baby was diagnosed with the protruding hymen membrane due to the fluid accumulation of the mucus in the uterus and vagina. The postnatal ultrasound examination to confirm the diagnosis hydrometrocolpos apart and find the cause of the obstruction disorders also an evaluation of other urogenital abnormalities. In this case, the

ultrasound during the postnatal successfully ensured the hydrometrocolpos abnormalities and determined the cause of the obstruction abnormalities in the imperforate hymen. However, the evaluation of other urogenital abnormalities within the normal limit and reveal no abnormalities.

In this case, postnatal MRI was performed for the evaluation of other urogenital disorders that can accompany the abnormality in the imperforate hymen. This evaluation is important because it determines the prognosis of this disorder in the future. On examination showed visible lesions resembling the uterine cavity shaped thin-walled, between the bladder and rectum are towards to the vaginal area. The lesion appeared to push the bladder to the right, with a border of bladder, rectum and other structures seem firm. There is light ectasis in the pelvicalyceal system of the left kidney. Pelvic inlet seemed normal. Bowel structure looks normal. Uterus: invisible picture of a normal uterus. Bladder: filled with enough fluid, invisible to the masses, seemed pushed into the right lateral side. The conclusions are a congenital anomaly of the Müllerian duct so that the uterus looks abnormal (**Fig. 3**). The displacement of lesions can cause mild hydronephrosis in the left kidney in the pelvic cavity.

In the description of postnatal MRI examination results, we can see a more detailed description of the structure of the urogenital system. Postnatal MRI has the advantage, could demonstrate and evaluate other disorders in the urogenital system more precisely. In this case, also the other urogenital abnormalities found that mild hydronephrosis left previously undiagnosed with ultrasound.

Previous research has demonstrated that elevated levels of maternal estrogen during pregnancy is the pathophysiology of accumulation in case of abnormal vaginal discharge with hydrometrocolpos with imperforate hymen. In other studies, Tseng et al. proved the increase of estradiol concentration in infant umbilical vein is 8,157 pg/mL (normal value on the Asian race is 5.480-8.020pg / mL) in those abnormalities (Karteris, et al. 2010).

### **The Risk and Complications of ydrometrocolpos**

In some cases, hydrometrocolpos led to an obstruction of the urethra causing further complications bilateral hydronephrosis, causing oligohydramnios, then this may cause fetal lung development. The masses pushed upwards due to the elongated and enlarged vagina resulting in pinching of the urethra, dysuria, acute urinary retention, hydronephrosis and hydroureter and worsen to kidney failure. In other cases, the mucous fluids can spread back to the peritoneum of the fetus and cause peritonitis (Güratefi, et al. 2000, Rouma, et al. 2011).

In this case, hydrometrocolpos could lead to complications such mild left hydronephrosis. This is a complication that is most often obtained as a result of this condition. Management of complications in the form of follow-up action through ultrasound evaluation after corrective surgery on imperforate hymen and evacuation hydrometrocolpos to relieve the suppressive effect on the urinary tract. The risk of complications is reduced with the rapid performed treatment of the cause of obstruction and discharge of mucus in the uterus and vagina.

### **The Procedures to Handle Hydrometrocolpos**

Examination of the external genitalia in newborns is highly recommended so that abnormalities could be diagnosed early. If the diagnosis of imperforate hymen could be identified without obstruction symptoms in uterovaginal fluids and the urinary tract. It is recommended to rigorously observed and treated with elective hymenotomy at puberty before menarche. However, if the abdominal mass obtained is accompanied by symptoms of urinary tract obstruction, then immediate surgery is necessary (Eksioglu, et al. 2012).

Surgical Procedures was meant to correct the imperforate hymen by making an elliptical incision or cross the membrane that covers the hymen with the fluid evacuation of clogged hydrometrocolpos. Then the vaginal mucosa hymen is sewn on to the ring to prevent adhesions and repeated obstruction. In some cases, reepithelization occurred on the edge of the hymen and needed repeated surgery. Bleeding, scar formation and stenosis of the vaginal opening is a major complication of this surgery (Rouma, et al, 2011).

In this case, an imperforate hymen with hydrometrocolpos and mild left hydronephrosis was found. There was an obstruction in uterovaginal fluids and the urinary tract in this case. Because it is necessary for immediate surgery to prevent the risk of more severe complications. Surgery to correct hydrometrocolpos and imperforate hymen was done in the form of hymenotomy and marsupialization and fluid evacuation of hydrometrocolpos. Management of mild left hydronephrosis was done with conservative treatment then followed-up by ultrasound after surgery. After the surgery, the suppressive effect of hydrometrocolpos and hydronephrosis was relieved.

In this patient, follow-up ultrasound after surgery revealed no fluid in the abdominal cavity and no hydronephrosis of the left kidney. On examination, one month after surgery found no symptoms with the holes on either hymen. Postoperative imaging examination is recommended to see improvement after surgery (Eksioglu, et al. 2012).

### **Prognosis of Hydrometrocolpos**

Prognosis in abnormality of single imperforate hymen is excellent. In general, the prognosis of

hydrometrocolpos is good, especially when diagnosed and treated early. Early diagnosis and treatment of obstruction vagina would improve pregnancy outcome by reducing the risk of haematometra and haematosalpinx which can cause pelvic endometriosis. Endometriosis and infertility is a complication that many were reported in the case of obstruction of the vagina (Rouma, et al, 2011). In this case, imperforate hymen with hydrometrocolpos and mild left hydronephrosis was treated. The prognosis, in this case, is excellent.

newborn baby from a pregnant woman at term who was referred to Dr. Soetomo hospitals for the suspected congenital anomaly. The postnatal examination obtained a female baby with cystic mass interlabial and postnatal ultrasound and the MRI reveals hydrometrocolpos concluded an abnormality in newborns with imperforate hymen. Hymenotomy and marsupialization was performed to evacuate fluid of hydrometrocolpos. On ultrasound evaluation of postoperative no longer liquid in the uterine cavity and no hydronephrosis was found. At a 1-month follow-up after surgery, no symptoms were reported.

## CONCLUSION

One case of hydrometrocolpos has been reported in newborns with imperforate hymen. This patient is a

## REFERENCES

- Adaletli, I., Ozer, H., Kurugoglu, S., Emir, H., & Madazli, R. (2007). Congenital imperforate hymen with hydrocolpos diagnosed using prenatal MRI. *American Journal of Roentgenology*, 189(1), W23-W25.
- Azinar, A. D., Annas, J. Y., Primariawan, R. Y., & Hardianto, G. (2017). Treatment of cervical agenesis with minimally invasive therapy: Case report. *Gynecology and minimally invasive therapy*, 6(4), 202-204.
- Bableswhar, A., Al Amer, S., & Kalis, N. N. (2018). Congenital Heart Diseases in Noonan's Syndrome-Mitral Valve Anomalies: Important Cause of Left Ventricular Outflow Tract Obstruction. *Bahrain Medical Bulletin*, 40(4), 215-218.
- Eksioglu, A. S., Maden, H. A., Cinar, G., & Yildiz, Y. T. (2012). Imperforate hymen causing bilateral hydronephrosis in an infant with bicornuate uterus. *Case reports in urology*, 2012.
- Gupta, M., Bajwa, S. J. S., & Gupta, M. (2014). Diagnostic dilemmas in management of neonatal hydrometrocolpos: A crucial role of magnetic resonance imaging. *International Journal of Health & Allied Sciences*, 3(4), 251.
- GÜRATEfi, B., Kazez, A., Sapmaz, E., Bulgan, E., & Yayla, M. (2000). Prenatal diagnosis of congenital imperforate hymen.
- Karteris, E., Foster, H., Karamouti, M., & Goumenou, A. (2010). Congenital imperforate hymen with hydrocolpos and hydronephrosis associated with severe hydramnios and increase of maternal ovarian steroidogenic enzymes. *Journal of Pediatric and Adolescent Gynecology*, 23(3), 136-141.
- Rouma, B., Aldrink, J., Finkelstein, J., Ginsburg, H. (2011). Hydrometrocolpos. In: Ameh E, Bickler S, Lakhoo A, Nwomeh B, Poenaru D, editors. *Pediatric Surgery: A Comprehensive Text for Africa* [Internet]. 1st ed. Seattle: The Global Help Organization; p. 672-7. Available from: [https://global-help.org/products/paediatric\\_surgery\\_a\\_comprehensive\\_text\\_for\\_africa/](https://global-help.org/products/paediatric_surgery_a_comprehensive_text_for_africa/)
- Smit-Fun, V. M., & Buhre, W. F. (2019). Heart failure in adult patients with congenital heart disease. *Anesthesiology clinics*, 37(4), 751-768.
- Toor, R. A., Sayyad, M. H., Nasr, N., Sajjad, S., Shah, S. A. A., & Manzoor, T. (2016). Efficiency Enhancement of Dye Sensitized Solar Cells with a Low Cost Co-Adsorbant in N719 Dye. *International Journal of Sustainable Energy and Environmental Research*, 5(3), 46-50
- Tseng, J. J., Ho, J. Y. P., Chen, W. H., & Chou, M. M. (2008). Prenatal diagnosis of isolated fetal hydrocolpos secondary to congenital imperforate hymen. *Journal of the Chinese Medical Association*, 71(6), 325-328.
- Vitale, V., Cigliano, B., & Vallone, G. (2013). Imperforate hymen causing congenital hydrometrocolpos. *Journal of ultrasound*, 16(1), 37-39.